ARTICLE IN PRESS
+ MODEL
Journal of Plastic, Reconstructive & Aesthetic Surgery (2017) xx, 1—8

Composite breast reconstruction: Implant-based breast reconstruction with adjunctive lipofilling

C.E. Sommeling [a], K. Van Landuyt [a], H. Depypere [b], R. Van den Broecke [b], S. Monstrey [a], P.N. Blondeel [a], W.A. Morrison [c,d,e,f], F.B. Stillaert [a,*]

[a] *Department of Plastic and Reconstructive Surgery, University Hospital Ghent, Ghent, Belgium*
[b] *Department of Gynaecology, University Hospital Ghent, Ghent, Belgium*
[c] *O'Brien Institute Dept. of St Vincent's Institute, Melbourne, Australia*
[d] *University of Melbourne, Dept. of Surgery at St Vincent's Hospital, Melbourne, Australia*
[e] *Faculty of Health Sciences, Australian Catholic University, Melbourne, Australia*
[f] *Victorian State Government's Department of Innovation, Industry and Regional Development's Operational Infrastructure Support Program, Melbourne, Australia*

Received 24 December 2016; accepted 12 May 2017

KEYWORDS
Lipofilling;
Tissue expansion;
Breast reconstruction;
Breast implant

Summary *Introduction:* Options for breast reconstructions enclose autologous tissue transfers or implants. Fat grafting is gaining more interest in this specific field of breast surgery. This study concentrates on the technique and aesthetic results of breast reconstruction with fat grafts combined with implants, in women who have undergone total mastectomy.
Methods: Breast reconstructions (n = 23) was performed using a protocol of intratissular expansion with serial deflation-lipofilling. In order to achieve the best aesthetic outcome, an additional small implant was placed. A retrospective data analysis was performed. In all patients a tissue expander was placed at the time of mastectomy or after removal of a previous breast reconstruction. The mean of lipoaspirate material for the reconstruction was 333 mL (range 120—715 mL). To create an adequate volume of the reconstructed breast, a supplementary small implant was placed, with a mean volume of 222 mL (range 125—375 mL). The mean follow-up was 33 months (range 19—50 months).
Results: A MRI analysis was performed in eight patients at least 9 months after the last lipofilling procedure, demonstrating a mean of 171 mL (range 64—538 mL) of transferred fat, a mean fat survival of 53% and a volume ratio of fat graft/implant of 0.97 (range 0,3—3,8).

* Corresponding author.
E-mail address: filip.stillaert@ugent.be (F.B. Stillaert).

http://dx.doi.org/10.1016/j.bjps.2017.05.019

Please cite this article in press as: Sommeling CE, et al., Composite breast reconstruction: Implant-based breast reconstruction with adjunctive lipofilling, Journal of Plastic, Reconstructive & Aesthetic Surgery (2017), http://dx.doi.org/10.1016/j.bjps.2017.05.019

Conclusion: This composite technique of using autologous fat tissue and implants shows aesthetic pleasant results and must be considered as a valid alternative in a subset of patients. Further investigations to optimize the fat graft take must be encouraged.

Introduction

Breast reconstruction with the fat grafting technique has been described.[1–4] The disadvantage is the unpredictable resorption rate, which affects the final volume and aesthetic appearance of the reconstructed breast. Fat grafting for breast reconstruction is mainly indicated in a specific group of patients that are not suitable for microsurgical tissue transfer or for patients not willing to undergo major invasive surgery. Patient selection is primordial before fat grafting is chosen as a reconstructive approach. Patients need to be motivated to undergo several fat grafting sessions, present with enough donor tissue and have small to moderate-sized breasts. When those selection criteria are not met, an implant-based reconstruction is the final alternative. However, implant-based breast reconstructions use foreign material that has an impact on surrounding tissues and induces scar formation that can be troublesome at the long-term.[5,6] A composite approach where the implant is used in combination with fat grafting could not only lower the volume and surface area of foreign material (the implant), but also transform the implant-based reconstruction into a more natural looking breast with less visible and palpable implant edges. Additionally, these kinds of reconstructions necessitate sufficient tissue coverage of the implant, which is traditionally provided by the retropectoral positioning of the implant. Breast animation, progressive thinning of the pectoral muscles or migration of the implant are well-known side-effects of this approach.[5] With the addition of lipofilling, the position of the implant could possibly be changed to a more prepectoral position as the subcutaneous layers of the mastectomy flaps could be thickened by grafted fat. However, fat grafting in the same operative time of the mastectomy is often not possible in the underperfused, thin mastectomy flaps. Alternative recipient sites such as the pectoral muscle have been described.[7] It is obligatory to incorporate a compliant recipient site for injection of fat grafts, preferably in the subcutaneous region, that prevents diffusion of those grafts within the mastectomy pocket. We implied a working algorithm that generates such a recipient site in composite breast reconstruction (CBR).

Patients and methods

A retrospective analysis of data on breast reconstruction using a protocol of intratissular expansion with serial deflation-lipofilling sessions and an additional implant was performed in 15 patients. Bilateral breast reconstructions were done in eight patients, in total 23 breasts were

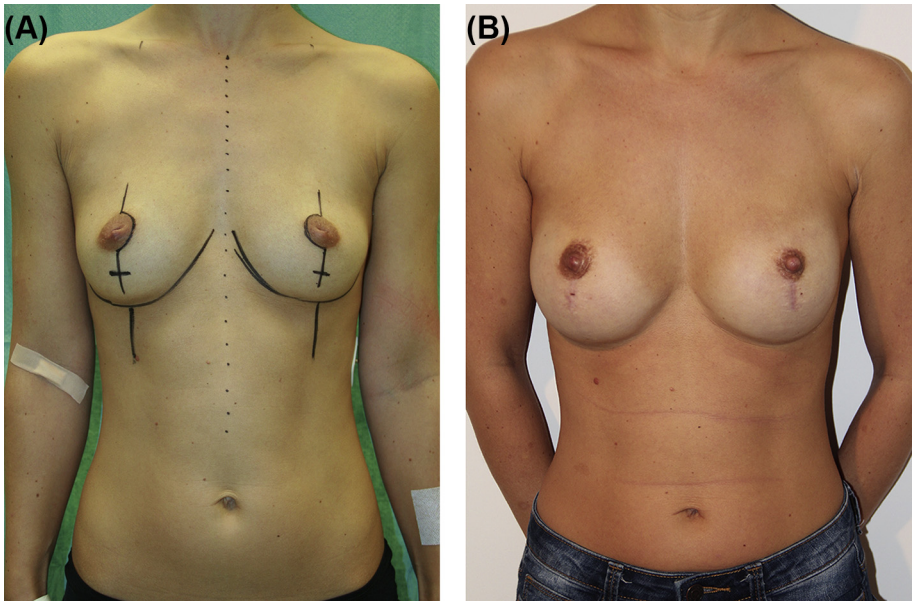

Figure 1 (A) Preoperative drawing of prophylactic bilateral mastectomy in a 37-year-old patient through a vertical incision on the skin envelope. (B) Reconstruction with prepectoral, anatomical, polyurethane implants (225 cc) and fat grafting (right side 250 cc, left side 260 cc) with aesthetically unpleasant visible scars 2 years after the reconstruction.

Please cite this article in press as: Sommeling CE, et al., Composite breast reconstruction: Implant-based breast reconstruction with adjunctive lipofilling, Journal of Plastic, Reconstructive & Aesthetic Surgery (2017), http://dx.doi.org/10.1016/j.bjps.2017.05.019

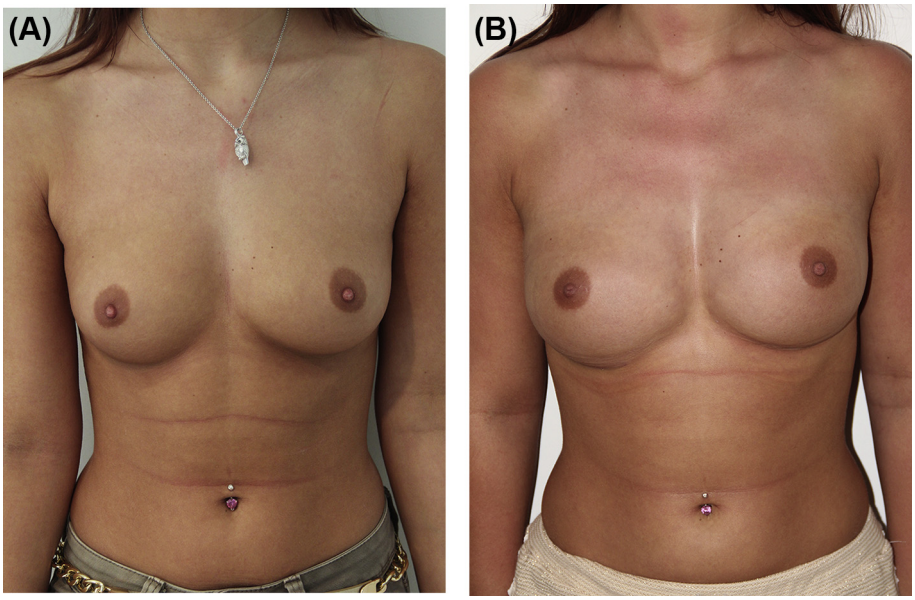

Figure 2 (A) Preoperative view of a prophylactic bilateral mastectomy in a 24-year-old patient through an extended inframammary incision. (B) The reconstruction with prepectoral positioning of round implants (280 cc) and fat grating (175 cc right and 195 cc left) is far more aesthetic compared to incisions on the skin envelope (8 months after the reconstruction).

reconstructed. Secondary reconstructions involved six breasts. Mean age of the patients was 46 years (range, 24—64 years). Procedures were executed between October 2011 and April 2015. The local ethics committee approved study methodology.Exclusion criteria included smokers, insufficient donor fat tissue and unmotivated patients.

Surgical procedure

All patients were marked preoperatively in the upright position. Markings included the limits of planned dissection, the existing inframammary folds in primary and the proposed new inframammary fold in secondary breast reconstruction respectively. Surgery was performed under general anaesthesia. Prophylactic mastectomy in BRCA-patients was performed through an incision that extended along the length of the inframammary fold. In such, the aesthetic appearance of the reconstructed breast was far more pleasant compared to an approach where visible incisions were placed on the skin envelope (Figures 1A—B and 2A—B). In secondary reconstructions the mastectomy and insertion of the expander were performed through an inframammary

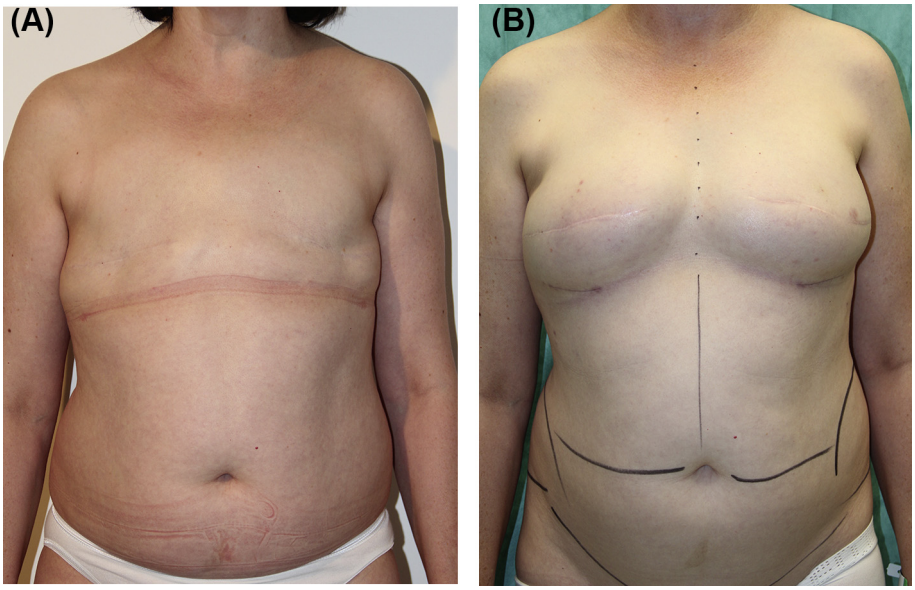

Figure 3 In secondary breast reconstructions expanders were inserted through an inframammary incision to avoid reopening of pre-existing mastectomy scars. The incision will be hidden in the inframammary fold after completion of the reconstruction. (A) Pre-operatively view. (B) View after fully inflated tissue expander.

Please cite this article in press as: Sommeling CE, et al., Composite breast reconstruction: Implant-based breast reconstruction with adjunctive lipofilling, Journal of Plastic, Reconstructive & Aesthetic Surgery (2017), http://dx.doi.org/10.1016/j.bjps.2017.05.019

Figure 4 (A—B) Prophylactic mastectomy performed through an inframammary incision with prepectoral expanders in place in full expansion at 8 weeks postoperatively. (C) Injection of 305 cc of fat in each breast envelope (total of 3 sessions) and insertion of an anatomical implant of 125 cc in the prepectoral position.

fold incision to preserve the integrity of the skin envelope (Figure 3). This approach avoids reopening of incisions on the anterior part of the skin envelope and prolonged wound healing on the anterior aspect of the breast.

Breast reconstruction was performed in several stages with initial insertion of a tissue expander (CPX4 Contour Profile Tissue Expander, Mentor™) and a closed suction drain. The expander was filled intraoperatively with 50 cc of Nacl 0.9% enriched with 5 cc methylene blue. Oral antibiotics were prescribed for 5 days (Amoxicillin 500 mg/ Clavulanic acid 125 mg). Patients were seen at the outpatient clinical after 2 weeks. Inflation of the expander was started with physiologic saline and continued for 8 weeks until sufficient expansion was achieved, if available the contralateral side was used a reference point (Figure 4A—C).

For the fat grafting technique, Coleman's structural fat grafting protocol was used.[1,2] The first session took place 8 weeks after insertion of the expander. In summary, donor sites (thigh, buttock area and abdomen) were infiltrated with a tumescent solution (1 L NaCL 0.9%, 20 mL Xylocaïn 1%, 1 mL Epinephrin 1.0 mg/1 mL). After a delay period of 20 min, fat was liposuctioned manually with a 50 cc syringe connected to a 3-hole Mercedes tip, 3 mm cannula. Lipoaspirate (LA) was transferred into 10 cc Luer-lock syringes and centrifuged at 12 G for 3 min (Sarstedt™, Centrifuge LC 24, 230 V). Before each lipofilling session, the expander was deflated slightly to accommodate the fat grafts in between

the skin and the generated capsula around the expander. Concentrated LA was injected subcutaneously with a single-hole blunt cannula (Coleman™ Concave Infiltration Cannula, Style I, 12 g) in a layered, multidirectional fashion. The amount of injected fat was directed intraoperatively by a clinical assessment of the skin's turgor and care was taken not to compromise capillary perfusion. Fat grafting sessions and expander deflation were performed with a 3-month interval until reasonable thickness of the skin envelope was obtained to cover the implant. The expander was eventually removed during the last lipofilling session through the existing or new inframammary incision and an implant was inserted.

Results

When analysing the data of 23 reconstructed breast we found a mean follow-up of 33 months (range, 19—50 months). The mean volume of grafted fat per breast was 313 mL (range, 120—715 mL) with a mean of 3.2 lipofilling sessions per patient (range, 2 to 5). Final implant size ranged from 125 to 375 mL (mean is 227 mL). In three patients, the expander and implant were positioned in a retropectoral position because of thin mastectomy skin flaps, with risk of exposure and consequently infection (Figure 5A—C). All three patients needed adjuvant chemo- or radiotherapy. All other patients had their expanders and implants inserted in a prepectoral plane. Five BRCA positive patients underwent prophylactic mastectomy (10 breasts) (Figures 3 and 4). In two patients the composite technique was chosen after previous failed autologous reconstruction. Adjuvant radiotherapy was given in six breasts after insertion of the expander. Those patients continued their reconstruction six months after completion of the radiation therapy. Six breasts had adjuvant chemotherapy after insertion of the expander and continued the reconstruction process six months after completion of the chemotherapy. One patient developed a severe infection with skin necrosis after the first lipofilling session, which necessitated removal of the expander (Figure 6A—E). In the other patients, there were no implant removals. All reconstructions

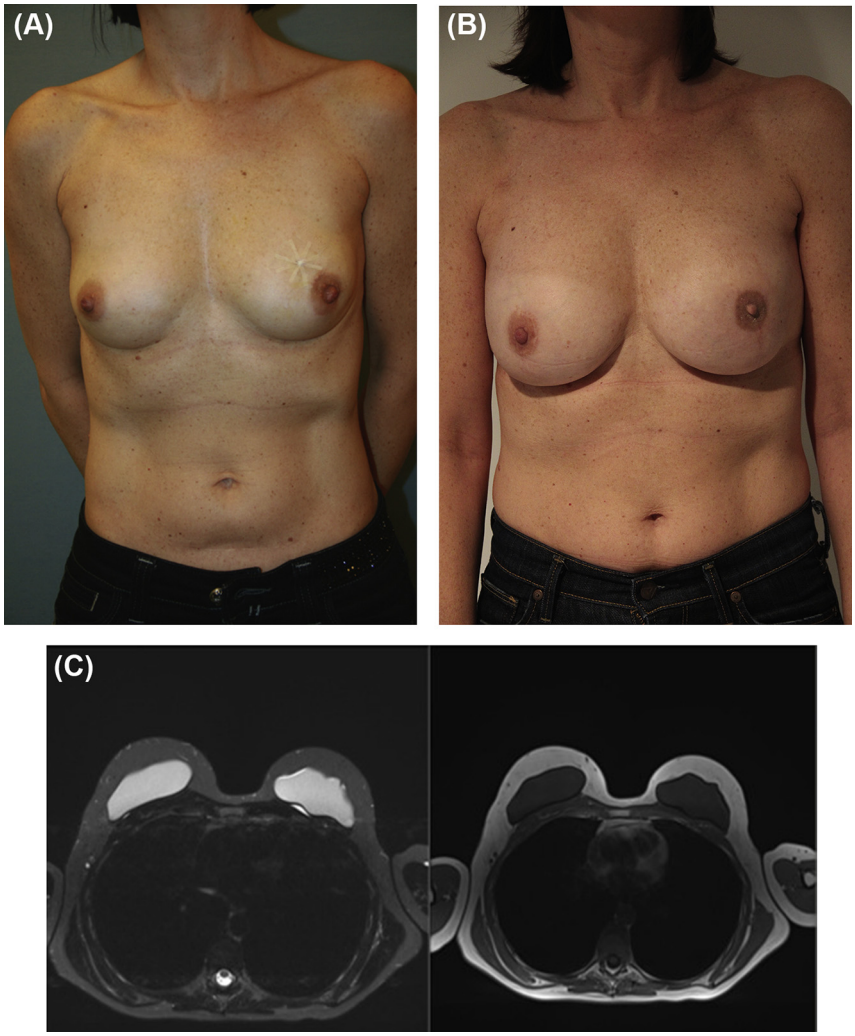

Figure 5 (A—B) Bilateral reconstruction with three sessions of fat grafting and injection of 215 cc in the right skin envelope and 225 cc in the left skin envelope. An additional implant of 245 cc was inserted in the prepectoral region. (C) The MRI scan (T1 on the left, T2 on the right) shows the thickness of the mastectomy flaps and sufficient coverage of the implants.

Please cite this article in press as: Sommeling CE, et al., Composite breast reconstruction: Implant-based breast reconstruction with adjunctive lipofilling, Journal of Plastic, Reconstructive & Aesthetic Surgery (2017), http://dx.doi.org/10.1016/j.bjps.2017.05.019

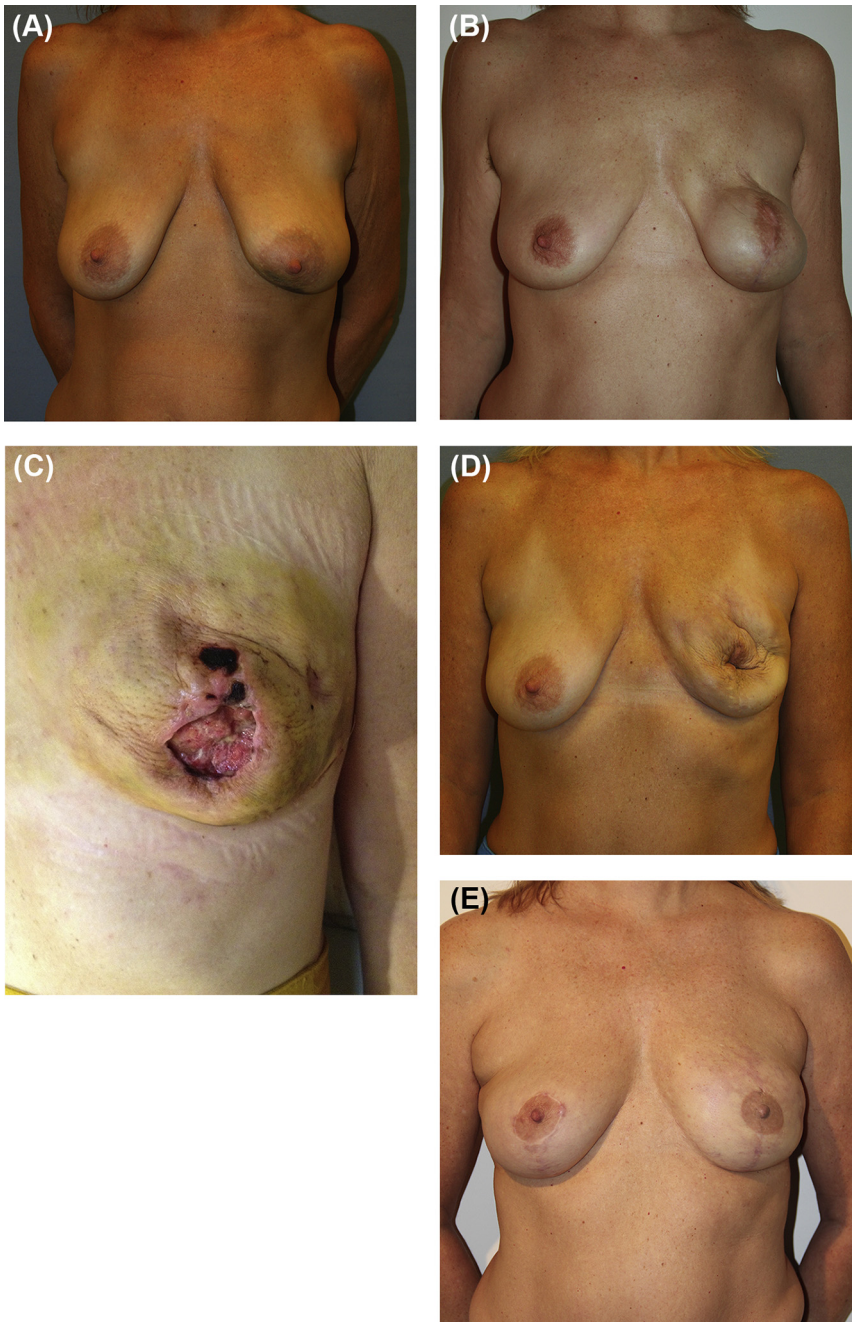

Figure 6 (A) Preoperative view. This 42 year-old patient underwent an autologous reconstruction with a deep inferior epigastric artery perforator flap, but the flap was lost at day four postoperatively. (B) An expander was inserted subcutaneously and fat grafting was initiated at 8 weeks. (C) After the first fat grafting session, she developed severe skin necrosis. (D) The wound was treated conservatively and healed in secondary intention. (E) Lipofilling was restarted after complete wound healing without additional insertion of an expander. She was diagnosed with a clotting disorder. She is seen one year after completion of the reconstruction and nipple reconstruction (715 cc of fat grafting in total and 335 cc implant in prepectoral position).

showed an improved thickness of the subcutaneous layers with a natural coverage of the implant.

Thirteen patients underwent preoperative breast MRI imaging. In eight patients (13 breasts) we performed a postoperative MRI imaging of the reconstructed breast at least nine months postoperatively (Table 1). The volume of the reconstructed breast was calculated on T1 images. Prepectoral adipose tissue within the breast pocket was marked in the transverse sections. The designated area of fatty tissue included roughly an area located 1 cm subcutaneously and 1 cm prepectoral to avoid misinterpretation with native adipose tissue. Every section (thickness of 1.50 mm, FS: 1.5) throughout the reconstructed volume was counted. The sum of all sections approximated the final reconstructed volume. With the MRI analysis we found a mean of 171 mL (range 64—538 mL) of remaining fat in the reconstructed breast. Comparing this with the size of the implant we calculated a mean volume ratio of 0.97 (range 0,3—3,8). No areas of tissue

Table 1 Overview of patients who had MRI imaging pre- and postoperative (n = number of fat grafting sessions).

Fat graft (cc) (n)	Implant (cc)	Residual fat volume (cc)	Fat/implant ratio	Fat survival %
305 (3)	125	73	0,59	24
305 (3)	125	75	0,6	25
690 (4)	140	538	3,8	78
310 (2)	190	215	1,13	69
510 (5)	165	231	1,4	45
520 (5)	165	201	1,2	39
215 (3)	245	154	0,62	72
225 (3)	245	170	0,72	78
200 (4)	170	64	0,3	32
120 (4)	170	75	0,4	63
435 (3)	210	235	1,2	54
185 (2)	270	84	0,3	45
170 (2)	270	111	0,4	65

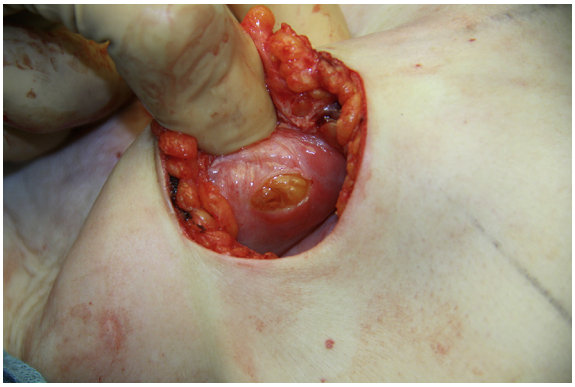

Figure 7 An intraoperative view on the capsule generated by the expander. An incision through the capsule shows herniation of viable grafted fat. This grafted fat provides additional thickness of the skin mastectomy flaps and provides additional coverage of the final implant.

necrosis and no residual capsule were seen, only some diffusely located small oil cysts were observed.

In all patients we have been able to obtain symmetrical outcomes with the creation of a 3D prepectoral volume that had an acceptable survival rate and long-term stability. Except for the mastectomy and expander insertion, all procedures were done in day clinic with a fast recovery of daily activities.

Discussion

Localized fat grafting has been used to correct breast deformities after surgery, radiation therapy or to correct congenital deformities.[4–6] Similar to other reports,[9–12] we have been able to perform total breast reconstructions using fat grafting only.[14] However, in our experience it is only feasible in a selected group of patients that present with sufficient donor tissue with small to moderate-sized breasts. In patients refusing microsurgical tissue transfer or patients that had previous failed reconstructions with larger volume breasts, the CBR approach is an elegant alternative to obtain a natural looking breast with a pleasant shape and projection.

The challenge is to compensate for the volume loss after the mastectomy that leaves the mastectomy skin flaps without any subcutaneous support previously provided by the breast glandular tissue and Cooper's ligaments. In theory, augmentation of the skin flaps after mastectomy could improve the look of an implant-based reconstruction. When those subcutaneous layers would even attain considerable thickness, even a prepectoral positioning of the implant could be considered because of sufficient tissue coverage. However, lipofilling of the subcutaneous layers of the mastectomy skin envelope is in most of the cases not feasible at the time of the mastectomy because of diffusion of the injected fat within the mastectomy pocket. Fat grafts need an anchoring point that maintains the grafts in their position and supports their survival. For these reasons, we opt to use tissue expansion. It is well-known that expansion creates a capsule that is well-vascularized and resistant after 8 weeks.[7,8] This autologous capsule could be beneficial to the fat grafting procedure when applied in breast reconstruction. It acts as a barrier that prevents diffusion of fat grafts within the mastectomy pocket (Figure 7) and it creates an additional and firm graft recipient site in between the outer skin envelope and the capsule itself. As grafts survive in the immediate postoperative period through imbibition, the present vascular plexus in the outer layer of the capsule can been seen as a nutritional source for fat grafts. By using the CBR approach, focus is set on the prepectoral space which is the natural space of the breast volume provided by the glandular breast tissue. Whenever feasible, this technique avoids the retropectoral position and its related disadvantages.[3] As described by others, the addition of fat grafting to an implant-based reconstruction has the advantage of thickening the skin envelope (Figure 7).[13] This subdermal layer of grafted fat acts as an aesthetical sheet that smoothens the appearance and transition areas of a traditional implant-based reconstruction. Grafted fat will minimize the risk of wrinkling of the skin and palpable or visible implant edges. The reconstructed breast will look and feel more natural especially with a prepectoral implant. With this position there is no risk of cranial migration of the implant due to muscle activity. Another advantage of adding volume to the subcutaneous layers is that an implant with a smaller volume can be introduced. This will have less impact on the surrounding tissues at the long-term, but will lead to extra projection, volume and shape.[15,16] Additional fat grafting is beneficial to smoothen out the aesthetic areas of the breast, such as the cleavage area or the lower pole (Figures 4C and 6E). Moreover, the CBR approach will avoid large donor scars and related donor site morbidity.

The main disadvantages are the need of multiples sessions of lipofilling at the operating theatre and multiple visits to the outpatient clinic for inflation of the tissue expander. There has been some concern regarding the oncological effect of grafted fat on dormant tumour cells. But latest reports did not show any negative effect of fat grafting to the breast and tumour progression.[17,18]

At the end of the procedure an implant is inserted to provide extra projection, volume, and shape and this

approach is similar to the composite breast augmentation approach[15,16]; the breast reconstruction becomes a breast augmentation at the end of the lipofilling sessions, as the final implant provides the needed projection and filling in a prepectoral position.

However, this technique does not replace the free tissue transfer approach, as this is still the gold standard in breast reconstruction at our department. The CBR approach is available for selected, motivated patients or as an ultimate approach in case of free flap failure.

Conclusion

Plastic surgery is driven by innovation and imagination. We have been introducing the composite breast reconstruction approach in our clinic to treat a specific group of patients that could not be helped with traditional techniques such as microsurgical tissue transfer. This composite approach has the advantage that the final appearance of the reconstructed breast looks more natural and that smaller implants can be used than in implant-based reconstructions. Disadvantage is the need for multiple procedures although they can be performed in day clinic admission.

Funding

None.

Conflict of interest statement

None of the authors declare any conflict of interest. The authors alone are responsible for the content and writing of this paper.

References

1. Coleman SR. Structural fat grafting: more than a permanent filler. *Plast Reconstr Surg* 2006;**118**(3 Suppl):108S—20S.
2. Pu LL, Coleman SR, Cui X, Ferguson Jr RE, Vasconez HC. Autologous fat grafts harvested and refined by the Coleman technique: a comparative study. *Plast Reconstr Surg* 2008; **122**(3):932—7.
3. Hammond DC, Schmitt WP, O'Connor EA. Treatment of breast animation deformity in implant-based reconstruction with pocket change to the subcutaneous position. *Plast Reconstr Surg* 2015;**135**(6):1540—4.
4. Kanchwala SK, Glatt BS, Conant EF, Bucky LP. Autologous fat grafting to the reconstructed breast: the management of acquired contour deformities. *Plast Reconstr Surg* 2009;**124**(2): 409—18.
5. Delay E, Garson S, Tousson G, Sinna R. Fat injection to the breast: technique, results, and indications based on 880 procedures over 10 years. *Aesthet Surg J* 2009;**29**(5):360—76.
6. Spear SL, Wilson HB, Lockwood MD. Fat injection to correct contour deformities in the reconstructed breast. *Plast Reconstr Surg* 2005 Oct;**116**(5):1300—5.
7. Bengston B, Ringler S, George E, DeHaan M, Mills K. Capsular tissue: a new local flap. *Plast Reconstr Surg* 1993;**91**(9):1073—9.
8. Pasyk K, Argenta L, Austad E. Histopathology of human expanded tissue. *Clin Plast Surg* 1987;**14**(3):435—45.
9. Khouri RK, Rigotti G, Khouri Jr RK, et al. Tissue-engineered breast reconstruction with Brava-assisted fat grafting: a 7-year, 488-patient, multicenter experience. *Plast Reconstr Surg* 2015;**135**(3):643—58.
10. Uda H, Sugawara Y, Sarukawa S, Sunaga A. Brava and autologous fat grafting for breast reconstruction after cancer surgery. *Plast Reconstr Surg* 2014;**133**(2):203—13.
11. Hammer-Hansen N, Jensen TB, Damsgaard TE. Delayed total breast reconstruction with brava. *Case Rep Surg* 2015;**2015**: 601904.
12. Khouri RK, Rigotti G, Cardoso E, Khouri Jr RK, Biggs TM. Megavolume autologous fat transfer: part I. Theory and principles. *Plast Reconstr Surg* 2014;**133**(3):550—7.
13. Hammond DC, O'Connor EA, Scheer JR. Total envelope fat grafting: a novel approach in breast reconstruction. *Plast Reconstr Surg* 2015 Mar;**135**(3):691—4.
14. Stillaert FB, Sommeling C, D' Arpa S, et al. Intratissular expansion-mediated, serial fat grafting: a step-by-step working algorithm to achieve 3D biological harmony in autologous breast reconstruction. *J Plast Reconstr Aesthet Surg* 2016; **69**(12):1579—87.
15. Auclair E, Blondeel P, Del Vecchio DA. Composite breast augmentation: soft- tissue planning using implants and fat. *Plast Reconstr Surg* 2013;**132**:558.
16. Auclair E, Anavekar N. Combined use of implant and fat grafting for breast augmentation. *Clin Plast Surg* 2015;**42**: 307—14.
17. Hamza A, Lohsiriwat V, Rietjens M. Lipofilling in breast cancer surgery. *Gland Surg* 2013 Feb;**2**(1):7—14.
18. Agha RA, Fowler AJ, Herlin C, Goodacre TE, Orgill DP. Use of autologous fat grafting for breast reconstruction: a systematic review with meta- analysis of oncological outcome. *J Plast Reconstr Aesthet Surg* 2015;**68**:143—61.